



DIET-RESPONSIVE ENTEROPATHY (RESPONSIVE TO A LOW-FAT HYPOALLERGENIC DIET)



AUTHORS

Luis Feo: DMV; Dipl. ECVIM. Co-responsible for the Internal Medicine Department AniCura Ars Veterinaria
Jordi Puig: DMV; Dipl. ACVIM and ECVIM. Co-responsible for the Internal Medicine Department AniCura Ars Veterinaria
Andrea Perez: DVM; Resident EVCIM-CA. Member of the Internal Medicine Department AniCura Ars Veterinaria

ABSTRACT

We describe the clinical case of an 8-month-old spayed female West Highland White Terrier with a history of chronic diarrhea and vomiting since 4 months of age who had received different elimination diets, antibiotics and glucocorticoids without complete clinical response. After diagnostic tests, it was confirmed that she had a chronic enteropathy and she was started on a new low-fat hydrolysed protein diet (Dechra SPECIFIC[®] Digestive Support Low Fat) with a very favorable response and achieving complete resolution of the clinical signs.



ANAMNESIS AND PHYSICAL EXAMINATION

Kala was referred to the Internal Medicine Service of the AniCura Ars Veterinary Hospital. She is an 8-month-old spayed female West Highland White Terrier with a history of intermittent episodes of listlessness, abdominal pain, vomiting and diarrhea (with mucus and fresh blood) since she was 4 months old. So far Kala had received different elimination diets (novel and hydrolysed protein) without adequate clinical response, in addition to having received metronidazole, glucocorticoids and probiotics (without response). **The general physical examination was compatible with normality at that time. The patient weighed 6 kg with a slightly low body condition (Body Condition Score 4/9).**

DIAGNOSTIC TESTS

Complete blood tests (haemogram and biochemistry) together with urinalysis and abdominal ultrasound were performed. No significant changes were observed in the blood or urinalysis. The abdominal ultrasound showed thickening of the muscular layer of the small intestine and mesenteric lymphadenomegaly.

Based on the findings observed in the tests performed, we performed as complementary tests the measurement of TLI, bile acids, basal cortisol, measurement of vitamin B12 (cobalamin) and a stool analysis, obtaining in all of them results compatible with normality.



LIST OF PROBLEMS AND DIFFERENTIAL DIAGNOSIS

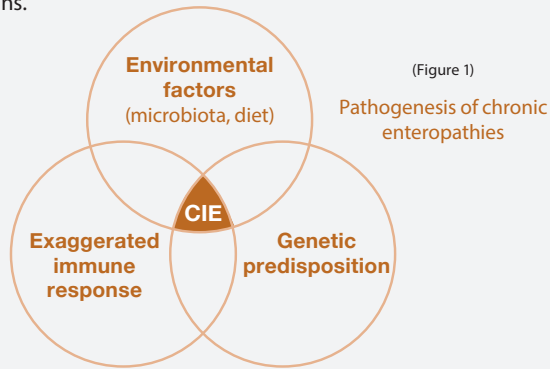
The list of problems included apathy, vomiting and chronic diarrhea. Differential diagnoses were:

- **Most frequent extra-gastrointestinal causes:** pancreatic diseases (pancreatitis, pancreatic insufficiency), liver diseases, metabolic disturbances (renal disease, electrolyte disorders) and endocrine diseases (hypoadrenocorticism).
- **Most frequent gastrointestinal causes:** chronic enteropathies (responding to diet, antibiotics or immunosuppressive treatment), intestinal parasites or gastrointestinal neoplasms.

Finally, we performed a digestive endoscopy with sampling for biopsy of the stomach, duodenum, ileum and colon. We highlight as relevant findings during the endoscopy the presence of generalized hyperemia in the stomach and proximal duodenum. In addition, moderate lacteal dilatation was observed, being compatible with lymphangiectasia. The histopathology report of the samples obtained by endoscopic biopsy of the stomach, duodenum and ileum were compatible with severe lymphoplasmacytic enteritis and moderate lymphangiectasia possibly secondary to inflammation.

DIAGNOSIS

After diagnostic testing, we determined that Kala had chronic inflammatory enteropathy (CIE) as the cause of the clinical signs.



CIE is characterized by an exaggerated immune response of multifactorial etiology. The immunopathology of enteropathies is the result of a complex interplay between elements of innate and adaptive immunity (Figure 1).

Histological evidence of intestinal mucosal inflammation confirms the diagnosis of chronic enteropathy but does not allow differentiation between the different subgroups of chronic enteropathies (enteropathies that respond to diet, antibiotics or immunosuppressants)¹. The sequential treatment with specific diets (hydrolysed or novel protein diets), antibiotic therapy and immunosuppressive treatment are the most commonly used strategies, determining the definitive diagnosis according to the response to treatment². Thus, we will consider as diet-responsive enteropathies those cases in which clinical signs resolve or significantly improve within 2-4 weeks after starting an elimination diet with a novel protein and carbohydrate source (commercial or home-made diet) or a hydrolysed protein diet³. Diet-responsive enteropathies are the most prevalent group (50-65%) of CIE. Individuals in this group are usually younger and have less severe clinical signs with respect to individuals classified in other subgroups of CIE⁴. The response to different hydrolysed protein diets varies, and an insufficient clinical response to one diet does not exclude the possibility of remission with another type of hydrolysed protein, which makes it essential to make different dietary changes (between 2-3 changes) before considering other treatments⁵.

Individuals who show improvement or resolution of their clinical signs after administration of an antibiotic for 2 weeks are classified as patients with antibiotic-responsive enteropathies⁴. Thirdly, individuals who require treatment with glucocorticoids or other immunosuppressive drugs are classified as patients with immunosuppressive-responsive enteropathies and will be those who do not respond to diet or antibiotics previously^{3,6}. Finally, up to 15-43% of individuals classified as having immunosuppressive enteropathies do not respond adequately to medical treatment. This subgroup is called non-responsive enteropathies, and is the subgroup with the worst long-term prognosis and a high mortality rate⁷.

CHOICE OF TREATMENT AND EVOLUTION

In Kala's case, different elimination diets had already been tried with partial or no response, so we switched to a hypoallergenic low-fat diet with hydrolysed salmon protein (Dechra SPECIFIC Digestive Support Low Fat). After completing 4 weeks on the new diet, we observed a complete response to the treatment. After 6 months from the start of the diet, she continued without any clinical signs. In this case, the use of a low-fat diet with hydrolysed salmon as monotherapy has been effective without the need to add other medical treatment



KEY POINTS TO CONSIDER IN THIS CASE

Diet has numerous direct effects on the gastrointestinal tract, including regulation of the microbiota, influencing the immune system, regulating gene expression and epigenetics, improving epithelial barrier function and affecting motility. Therefore, diet plays a central role in the pathogenesis of chronic enteropathies, and can act both as an aggravating factor of the disease itself and as a therapy for it⁸.

This case reflects several interesting points in relation to diet-responsive enteropathies.

Firstly, the importance in these cases of trying several elimination diets (hydrolysed or novel protein) in an orderly and serial manner before considering other treatments, especially in young patients with mild to moderate clinical signs.

On the other hand, it is noteworthy that this patient had already received a hydrolysed salmon diet without a positive response and another low-fat diet with highly digestible protein also without response. Therefore, the fact that Kala **responded to a low-fat hydrolysed salmon diet (Dechra SPECIFIC Digestive Support Low Fat)** shows that the combination of hydrolysed protein and low-fat strategies in the same diet can be a good alternative in patients with chronic enteropathy.

References

1. Washabau RJ, Day MJ, Willard MD, Hall EJ, Jergens AE, Mansell J, et al. Endoscopic, biopsy, and histopathologic guidelines for the evaluation of gastrointestinal inflammation in companion animals. *J Vet Intern Med.* (2010) 24:10–26. doi: 10.1111/j.1939-1676.2009.0443.x.
2. Makielski K, Cullen J, O'Connor A, Jergens AE. Narrative review of therapies for chronic enteropathies in dogs and cats. *J Vet Intern Med.* 2019 Jan;33(1):11–22. doi: 10.1111/jvim.15345. Epub 2018 Dec 6. PMID: 30523666; PMCID: PMC6335544
3. Allenspach K, Culverwell C, Chan D. Long-term outcome in dogs with chronic enteropathies: 203 cases. *Vet Rec.* (2016) 178:368. doi: 10.1136/vr.103557
4. Dandrieux JR. Inflammatory bowel disease versus chronic enteropathy in dogs: are they one and the same? *J Small Anim Pract.* (2016) 57:589–99. doi: 10.1111/jsap.12588.
5. Kathrani A, Hall E, A. Preliminary study assessing cytokine production following ex vivo stimulation of whole blood with diet in dogs with chronic enteropathy. *BMC Vet Res.* (2019) 15:185. doi: 10.1186/s12917-019-1940-7.
6. Erdmann C, Heilmann RM. Diagnostic and therapeutic approach to chronic inflammatory enteropathies in dogs. *Tierarztl Prax Ausg K Kleintiere Heimtiere.* (2017) 45:317–27. doi: 10.15654/TPK-170366
7. Allenspach K, Wieland B, Gröne A, Gaschen F. Chronic enteropathies in dogs: evaluation of risk factors for negative outcome. *J Vet Intern Med.* (2007) 21:700–8. doi: 10.1111/j.1939-1676.2007.tb03011.x
8. Kathrani A. Dietary and Nutritional Approaches to the Management of Chronic Enteropathy in Dogs and Cats. *Vet Clin North Am Small Anim Pract.* 2021 Jan;51(1):123–136. doi: 10.1016/j.cvsm.2020.09.005. Epub 2020 Oct 29. PMID: 33131914.

NEW DIGESTIVE SUPPORT LOW FAT DIETS

NEW Digestive Support Low Fat diets for dogs for nutritional support of a wide range of gastrointestinal conditions that benefit from a low level of dietary fat such as pancreatitis, EPI, protein-losing enteropathy, lymphangiectasia, cholestasis and hyperlipidaemia.



A combination of low fat with high levels of EPA and DHA and hypoallergenic ingredients make these diets suitable for a wide range of digestive disorders

- **Exceptionally low fat levels at 7% of dry matter** - make these diets suitable for the management of both moderate and severe cases of pancreatitis and cholestasis
- **Low fat level and high levels of EPA and DHA omega-3 from fish**, reducing triglyceride levels, make these diets suitable for the management hyperlipidaemia, which is considered as a potential cause of pancreatitis
- **With hypoallergenic ingredients, hydrolysed salmon and tapioca or potato starch**, these diets are also suitable for dogs with IBD and food allergies and for feeding during periods of reduced intestinal gut barrier

NEW DIGESTIVE SUPPORT LOW FAT DIETS

DIETARY CHARACTERISTICS

- **Low fat level at 7% of dry matter**
- **High digestibility** to ensure optimal intake of nutrients
- **With beneficial fibres, beta-glucans, fish oil and a blend of natural ingredients** to support a healthy gut microbiome, immune response and barrier function of the gut (Li et al. 2006, Mondo 2019)
- **Low allergenicity for support of GI-disorders** with potential involvement of adverse food reaction (the diets are based on hydrolysed salmon with tapioca (dry diet) or with potato starch (wet diet))
- **High levels of EPA and DHA omega-3** from fish supporting the body's natural anti-inflammatory processes
- **Supplementation with free nucleotides** supports both immune function and rapid repair of the gut, increasing villi length, aiding nutrient absorption and speed of return to full digestive health
- **Supplementation with AuraGuard** – A mixture of natural polyphenol containing plant extract and organic acids supporting gut barrier integrity and intestinal health

Balta I et al. (2021) Mixtures of natural antimicrobials can reduce *Campylobacter jejuni*, *Salmonella enterica* and *Clostridium perfringens* infections and cellular inflammation response in MDCK cells. *Cult Path* 13: 37.

Li J et al. (2006) Effects of β -glucan extracted from *Saccharomyces cerevisiae* on growth performance, and immunological and somatotropic responses of pigs challenged with *Escherichia coli* lipopolysaccharide. *J Anim Sci* 84: 2374-2381.

Mondo E et al. (2019) Role of gut microbiota in dogs and cat's health and diseases. *Open Vet J* 9 (3): 253-258.

Xenoulis PG et al. (2020) Serum triglyceride and cholesterol concentrations and lipoprotein profiles in dogs with naturally occurring pancreatitis and healthy control dogs. *J Vet Intern Med* 34: 644-652.

